

# Spectral OCT SLO Report

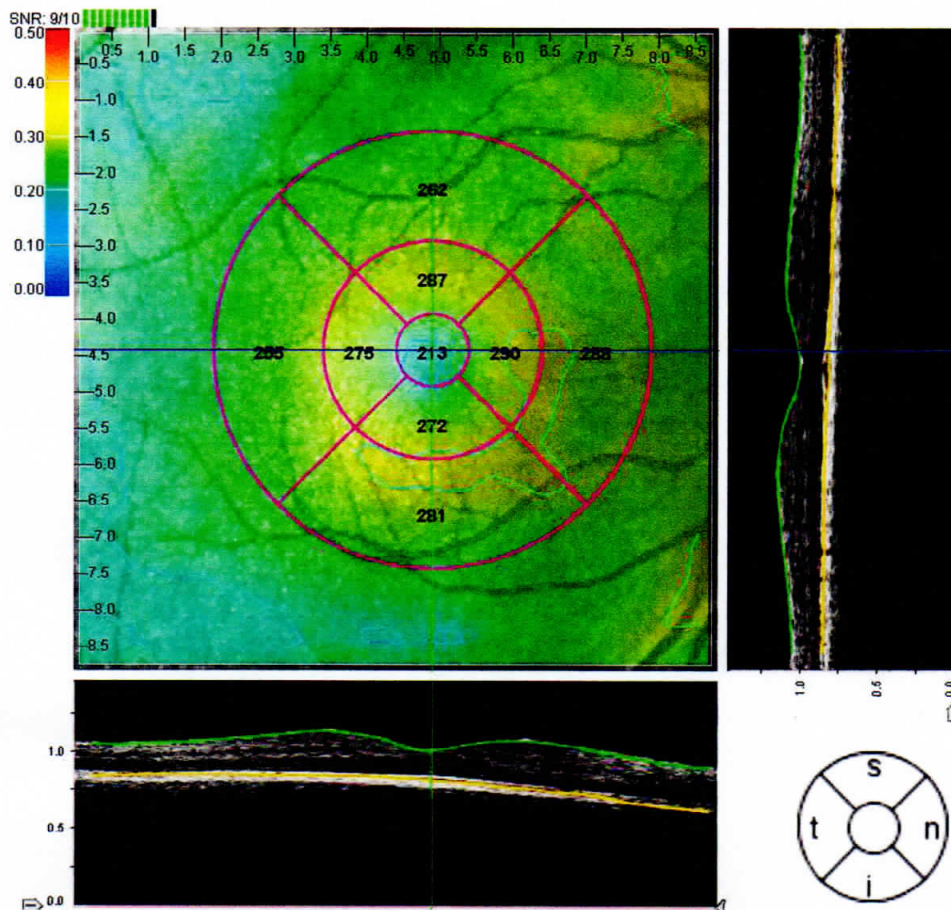
Patient Name: nitti, nicola

Patient ID: 890702146

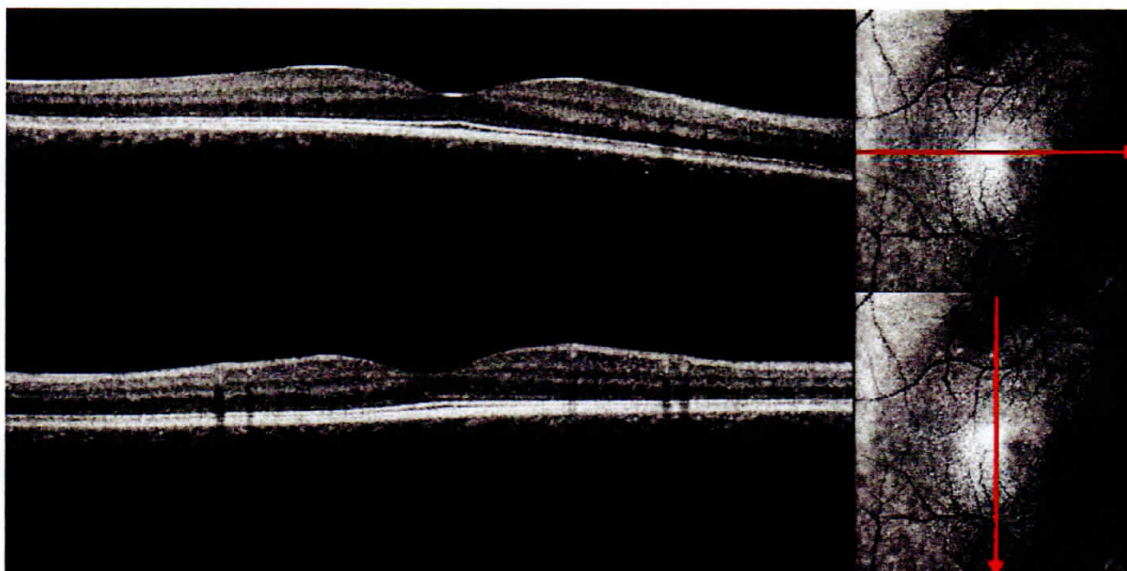
Description: OD

D.O.B.: Mar 7, 1980

Date: May 6, 2015



	Avg thick $\mu$	Volume $\mu$ L
Center	192	
Center circle	213	0.17
Superior inner	287	0.45
Temporal inner	275	0.43
Inferior inner	272	0.42
Nasal inner	290	0.46
Superior outer	262	1.38
Temporal outer	255	1.35
Inferior outer	281	1.48
Nasal outer	288	1.53
Totals	272	7.66



**Comments: OD:** Profilo retinico conservato con depressione foveale di normale morfologia e spessore. Membrana limitante interna, strati nucleari e plessiformi, complesso EPR-coriocapillare normalmente rappresentati in riflettività e spessore. Spessore foveale nella norma (192 microns). Esame nella norma.

POLICLINICO CASILINO  
 Dott.ssa CHIARA TARESI  
 U.O.S. Oftalmologica  
 N. Iscr. Albo Med. Prov. II 56494/RM

# Spectral OCT SLO Report

Patient Name: nitti, nicola

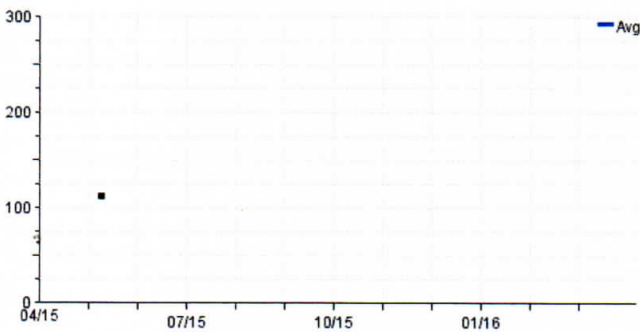
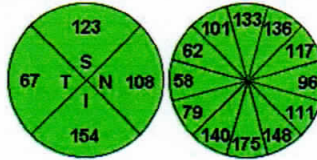
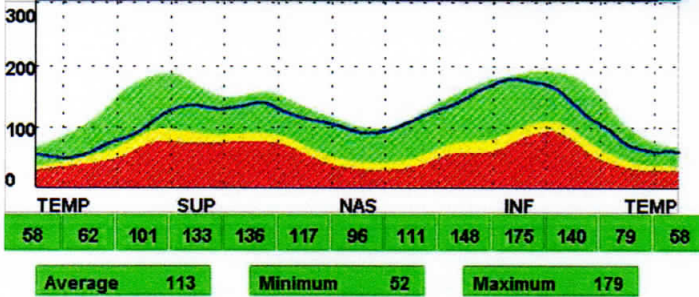
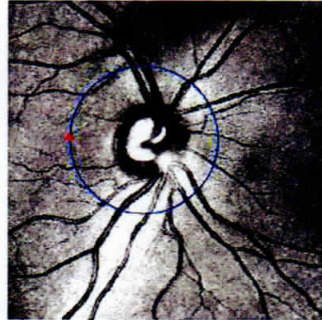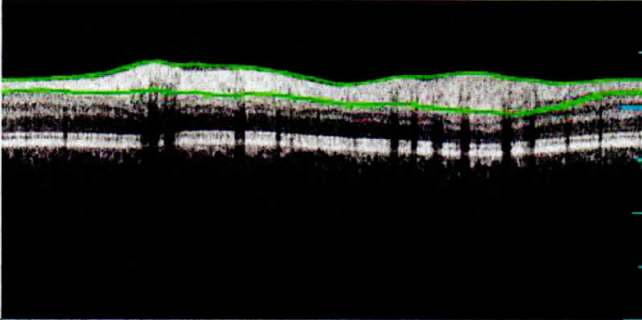
Patient ID: 890702146

Description: OD

D.O.B.: Mar 7, 1980

Date: May 6, 2015

SNR: 9/10



Comments: OD: normale lo spessore delle fibre nervose retiniche in tutti i settori

OPKO Instrumentation

POLICLINICO CASILINO  
Dott.ssa *ANILARA VARESI*  
U.O.S. Oculistica  
N. Iscr. Albo Med. Prov.li 56494/RM



# Spectral OCT SLO Report

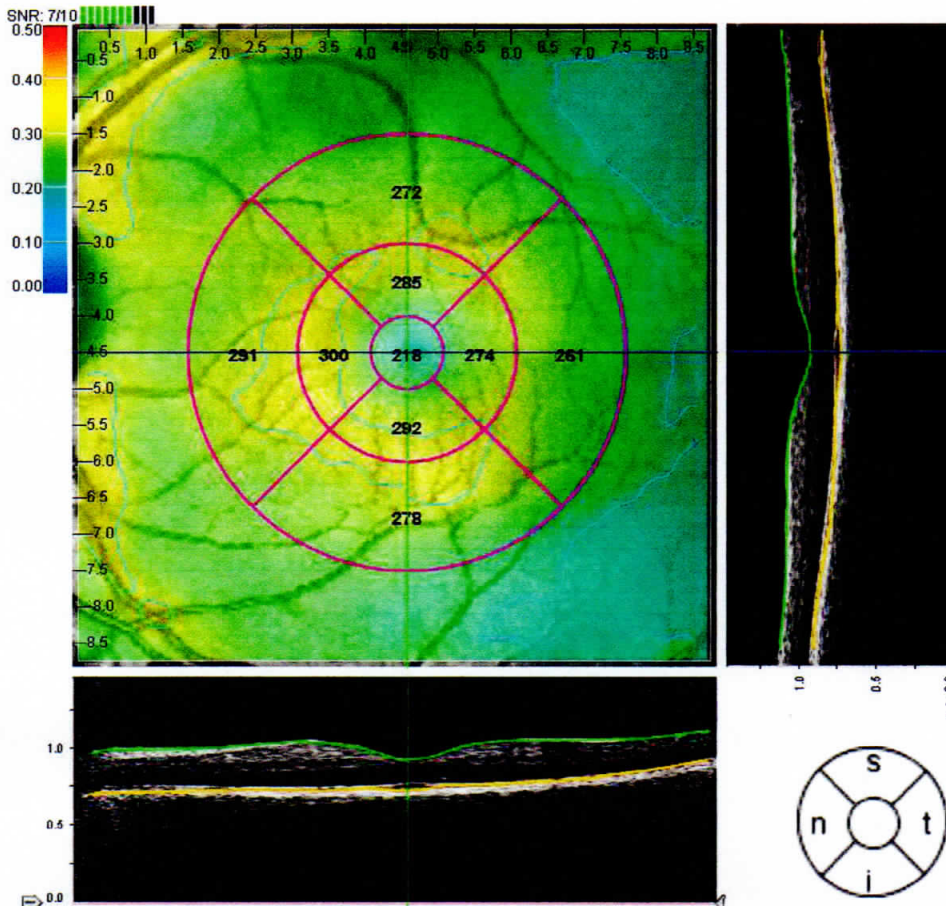
Patient Name: nitti, nicola

Patient ID: 890702146

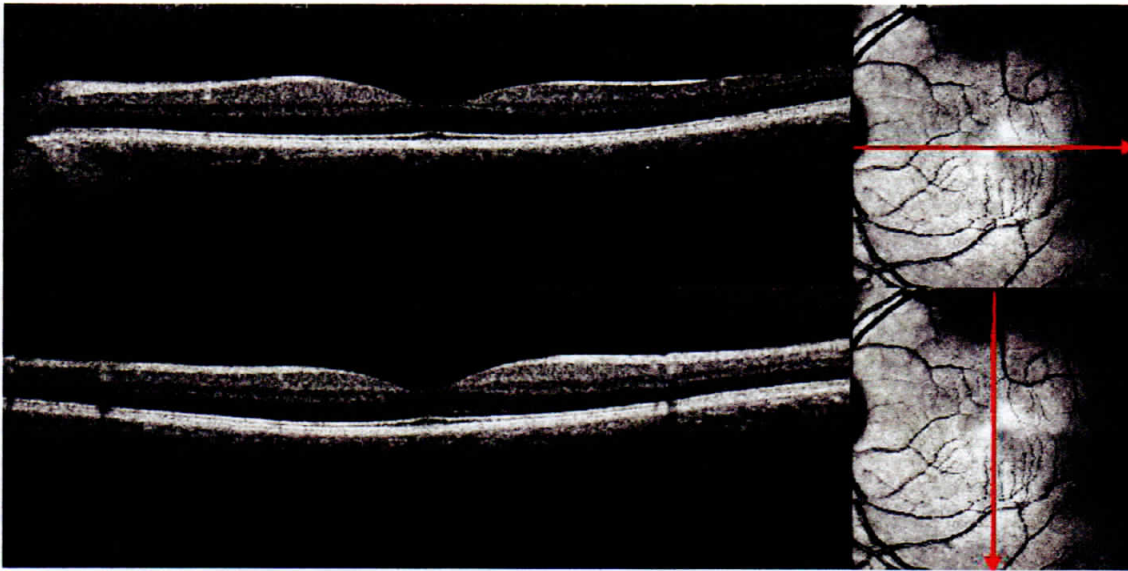Description: OS

D.O.B.: Mar 7, 1980

Date: May 6, 2015



	Avg thick $\mu$	Volume $\mu$ L
Center	203	
Center circle	218	0.17
Superior inner	285	0.44
Temporal inner	274	0.43
Inferior inner	292	0.45
Nasal inner	300	0.47
Superior outer	272	1.43
Temporal outer	261	1.39
Inferior outer	278	1.46
Nasal outer	291	1.54
Totals	277	7.80



**Comments: OS:** Profilo retinico conservato con depressione foveale di normale morfologia e spessore. Membrana limitante interna, strati nucleari e plessiformi, complesso EPR-coriocapillare normalmente rappresentati in riflettività e spessore. Spessore foveale nella norma (203 microns). Esame nella norma.

POLICLINICO CASILINO  
Dott.ssa *ANNA VARESI*  
U.O.C. Oculistica  
N. Iscr. Albo Med. Prov. II 56494/RM

# Spectral OCT SLO Report

Patient Name: nitti, nicola

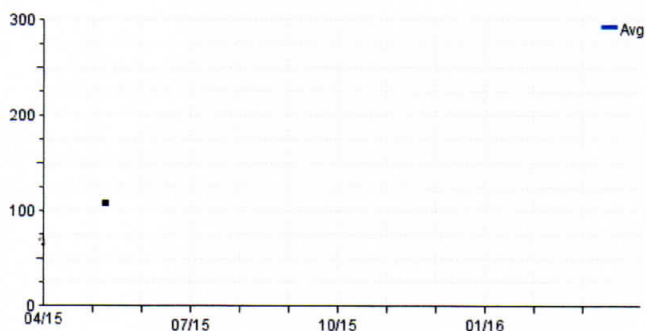
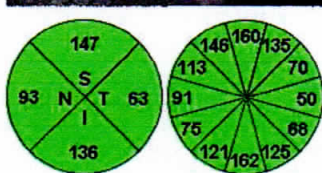
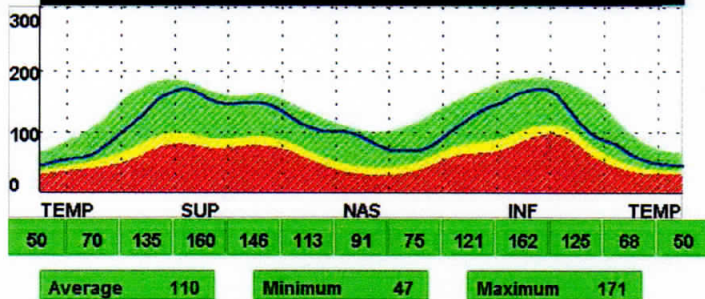
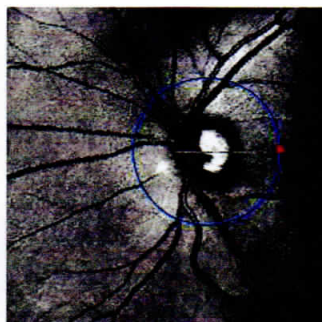
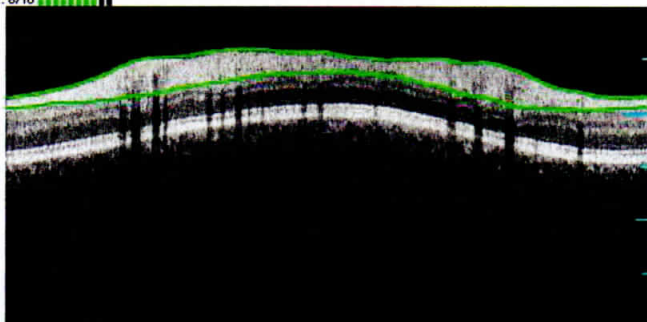
Patient ID: 890702146

Description: OS

D.O.B.: Mar 7, 1980

Date: May 6, 2015

SNR: 8/10



Comments: OS: normale lo spessore delle fibre nervose retiniche in tutti i settori

OPKO Instrumentation

POLICLINICO CASILINO  
Dott.ssa CHIARA VARESI  
U.O.S. Oculistica  
N. Iscr. Albo Med. Prov. LI 56494/R.